

Morphometric features of the right atrioventricular orifice in adult human hearts

M. Skwarek¹, J. Hreczecha², M. Dudziak³, J. Jerzemowski⁴, M. Szpinda⁵, M. Grzybiak²

¹Department of Sports Medicine, the Jędrzej Śniadecki Academy of Physical Education and Sport, Gdańsk, Poland

²Department of Clinical Anatomy, Medical University, Gdańsk, Poland

³Non-invasive Cardiovascular Diagnostic Unit, Institute of Cardiology, Medical University, Gdańsk, Poland

⁴Department of Anatomy and Anthropology, the Jędrzej Śniadecki Academy of Physical Education and Sport, Gdańsk, Poland

⁵Department of Normal Anatomy, the Ludwig Rydygier Collegium Medicum in Bydgoszcz, the Nicolaus Copernicus University, Toruń, Poland

[Received 12 October 2007; Revised 20 December 2007; Accepted 7 January 2008]

The normal data of the tricuspid valve complex is of great clinical importance in the light of progress in cardiosurgery and the development of novel operating techniques. A range of measurements for the right atrioventricular orifice in 96 human adult hearts was examined by means of anatomical dissection, inspection, examination, and statistical analyses. The length of the attachment of the anterior leaflet increased significantly between group I (aged 18–40 years) and group II (aged 41–64 years) in women only. In men there were no significant differences in this parameter between any of the three age groups. In addition, the attachment length of the posterior leaflet in women increased statistically in the second age group. In men, in contrast, the attachment length of the posterior leaflet did not increase significantly between the first and second age groups and became significantly larger only in oldest age group, consisting of men aged over 65. No statistically significant differences between the three age groups were found for the attachment length of the septal leaflet ($p > 0.05$). In female hearts significant increases in the frontal and sagittal dimensions of the tricuspid valve orifice were observed between the second age group and the group aged over 65. In male hearts both the frontal and sagittal dimensions increased significantly with advanced age. The right atrioventricular orifice expressed as the ellipse area was statistically greater than the triangular area ($p < 0.01$) in each age group. It should be noticed that both areas increased significantly during ageing. This study has demonstrated that the shape of the right atrioventricular orifice evolves during life, from a triangular shape to a more elliptical shape. (Folia Morphol 2008; 67: 53–57)

Key words: right atrioventricular orifice, attachment length of the tricuspid valve, tricuspid valve orifice area, statistical analysis, morphology, morphometry, human heart

INTRODUCTION

The anatomy of the tricuspid valvar complex is highly sophisticated [13, 18–20], but understanding of it may be helpful in the practice of cardiac surgery, especially in the partial transfer of leaflets of the tricuspid valve for mitral valve repairs [1, 2, 4]. The right atrioventricular valve region may be involved in severe cardiac malformations [5, 7–11, 15]. Surgical techniques of tricuspid valve repair have been developed that are equally effective in correcting purely functional and organic valvular incompetence [14]. The tricuspid valve is situated on the right atrioventricular orifice and joins two chambers of the heart which differ greatly in shape. Cross-sections of the right atrium performed parallel to the plane of the tricuspid valve resemble an ellipse or a circle. On the other hand, analogical cross-sections of the right ventricle appear more triangular. Comparison of the right atrioventricular orifice to these figures may be helpful in understanding which chamber exerts the greater influence on the shape of the tricuspid valve. Published works on the normal dimensions of the right atrioventricular orifice are surprisingly scant [12, 17]. Moreover, values accepted as normal are frequently based on angiography or echocardiography, methods known to have many sources of error.

The present study was undertaken in order to construct a normal range for the different dimensions of the tricuspid valve orifice, which may be helpful for cardiothoracic surgeons and invasive cardiologists, who use direct dimensions of this region.

The objectives for the present study were set to examine:

- the attachment length of the anterior, posterior and septal leaflets;
- the frontal and sagittal dimensions of the tricuspid valve attachment;
- the right atrioventricular orifice area;
- the circumference of the tricuspid valve attachment orifice;
- the evolution of the dimensions of the right atrioventricular orifice with ageing.

MATERIAL AND METHODS

The examinations were carried out on 96 formalin-fixed hearts, without malformations or pathological changes, of adult humans of both sexes (69 men, 27 women) who had died from non-vascular diseases and who had ranged in age from 18 to 90 years. The hearts were non-macerated and preserved by immersion in 4% neutral formalin solution and then dissected under a surgical microscope. The heart spec-

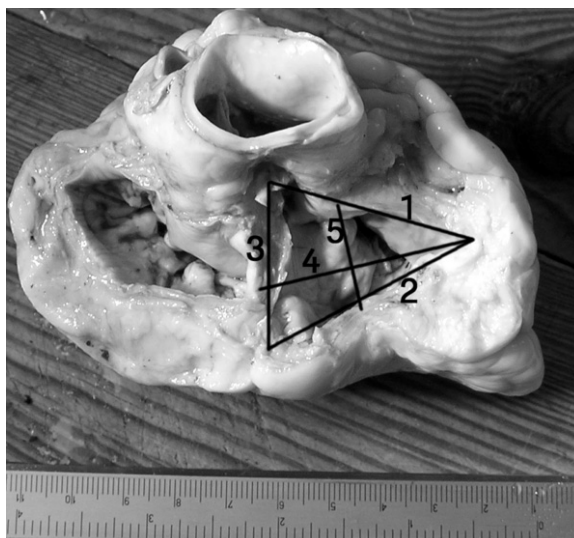


Figure 1. Measurement of the right atrioventricular orifice; the attachment lengths of the particular leaflets of the tricuspid valve: the anterior (1), posterior (2) and septal (3), the frontal (4) and sagittal (5) dimensions of the tricuspid valve attachment.

imens were grouped into three cohorts corresponding to age: 48 hearts were obtained from adults (39 men, 9 women) aged between 18 and 40 years (group I), 39 hearts were obtained from adults (25 men, 14 women) aged between 41 and 64 years (group II), and 9 hearts were obtained from adults (5 men, 4 women) aged 65 and above (group III).

Dissection of the fixed hearts was performed according to standard autopsy techniques. Each heart was opened along the path of the blood flow, from the inferior vena cava orifice to the right atrioventricular orifice. Afterwards, using a nonius scale for each heart, the following six measurements (1–6) were made of the right atrioventricular orifice (Fig. 1): the anterior (1), posterior (2) septal (3), frontal (4) and sagittal (5) attachment lengths of the particular leaflets of the tricuspid valve and, by means of a flexible millimetre ruler, the atrial circumference of the tricuspid valve attachment (6). The frontal dimension of the tricuspid valve was measured from the commissure between the anterior and septal leaflet of the tricuspid valve along the axis of the right atrioventricular orifice to the sharp margin of the right ventricle. The sagittal dimension was measured perpendicularly to the frontal dimension at the midpoint of its length.

On the basis of examination of these measurements a triangle was constructed and an ellipse to determine the shape of the atrioventricular orifice. The triangle was marked using dimensions 1–3, and

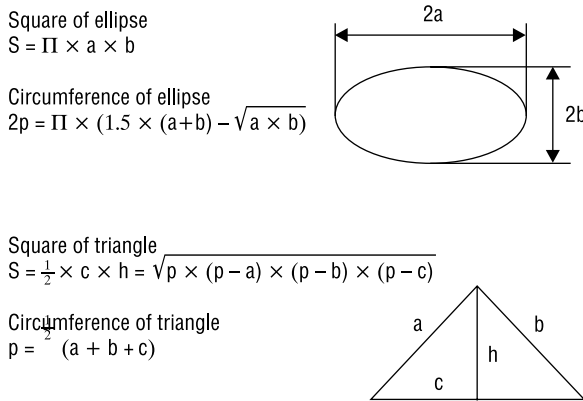


Figure 2. The area and perimeter of the triangle and the area and circumference of the ellipse.

the ellipse was based on dimensions 4 and 5. The areas of these figures were calculated according to formulae, as displayed in Figure 2. Finally, the results obtained were statistically analysed by one-way analysis of variance (ANOVA) for independent variables (means for three groups). Student's t test for two independent variables was used to determine the statistical significance of gender differences.

RESULTS

The attachment length of the anterior leaflet ranged in men from 33.56 ± 6.32 mm to 34.2 ± 6.57 mm, and in women from 31.17 ± 7.10 mm to 31.88 ± 5.84 mm. Statistical differences were observed between age groups I and II in women, only ($p < 0.05$). In men there were no significant differences between the age groups for this parameter. In addition, the attachment length of the posterior leaflet increased significantly from 27.61 ± 6.61 mm (group I) to 36.22 ± 9.80 mm (group II) in the female hearts. In the male hearts the attachment length of the posterior leaflet did not differ significantly between the first and second age groups, increasing from 28.56 ± 7.10 mm to 28.9 ± 6.56 mm. This length was significantly greater (38.4 ± 11.28 mm) in those hearts taken from cadavers aged over 65 years. No statistically significant differences were found between the three age groups for the attachment length of the septal leaflet ($p > 0.05$).

In female hearts significant increases in the frontal and sagittal dimensions of the tricuspid valve orifice were observed between the second age group and the group aged over 65, from 26.31 ± 4.74 mm to 29.13 ± 1.84 mm, and from 18.16 ± 4.36 mm to 22.0 ± 0.82 mm, respectively. Both the frontal and

sagittal dimensions increased significantly with ageing in male hearts, from 26.33 ± 4.25 mm to 31.1 ± 3.49 mm for the frontal dimension, and from 18.67 ± 4.97 mm to 22.8 ± 4.27 mm for the sagittal dimension. The right atrioventricular orifice expressed as the ellipse area was statistically greater than the triangle area ($p < 0.01$) in each age group (Table 1). It should be noted that both areas increased significantly with advanced age. The morphometric data indicated that the right atrioventricular orifice changed its shape with ageing. In the younger hearts it resembled a triangle, while in the older hearts it was elliptical (Fig. 3A, B).

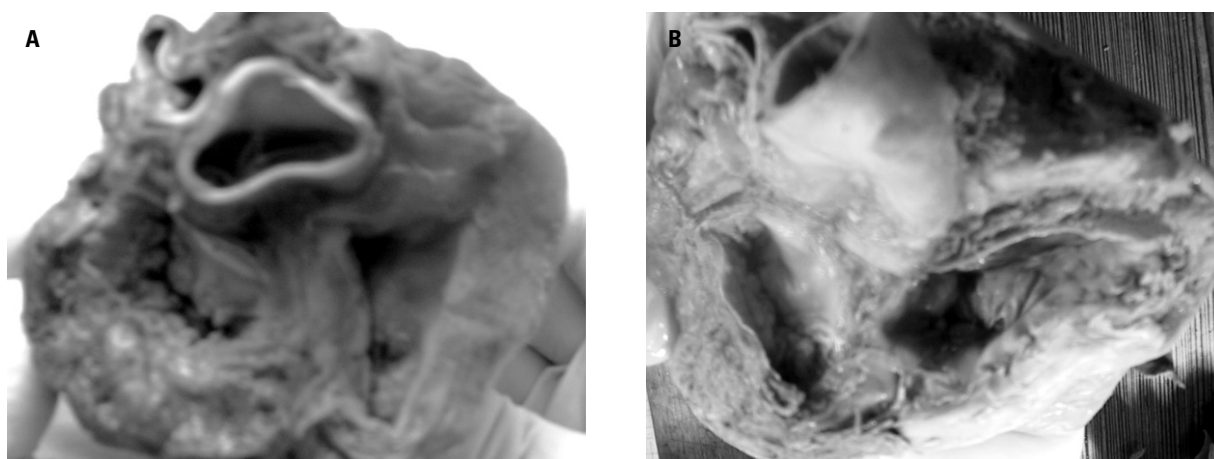
DISCUSSION

The leaflets of the tricuspid valve develop equally from the endocardial cushion tissues and the myocardium. The myocardium contributing to the tricuspid valve comes from two sources: the tricuspid gully complex and the developing supraventricular crest [6]. The anterior leaflet is the largest and is attached chiefly to the atrioventricular junction from the anteroposterior commissure to the anteroseptal commissure on the posterolateral aspect of the supraventricular crest, but it extends along its septal limb to the membranous septum. The posterior leaflet is mural in all of the attachment length, originating at the anteroposterior commissure and ending at the posteroseptal commissure. The septal leaflet attachment passes from the posterior ventricular wall, goes across the muscular septum and then angles across the membranous septum to the anteroseptal commissure. The right atrioventricular orifice, from its atrial aspect, has a clear line of transition from the atrial wall or septum to the bases of the valvar leaflets.

The right atrioventricular orifice is the largest valve orifice. According to Silver et al. [16], its circumference reached a value of 114 ± 11 mm in males and 108 ± 13 mm in females. Our results, in which the circumference of the tricuspid valve ranged from 107.28 ± 16.76 mm to 120.9 ± 20.95 mm in men and from 104.04 ± 16.76 mm to 110.75 ± 14.38 mm in women, corresponded to these. The tricuspid valve orifice has been described as almost circular or oval. When roughly triangular with rounded angles, its marginal sectors are described as anterior, posterior and septal, corresponding to the bases of the valvar leaflets [16]. This study concerned the specimens of a limited number of hearts but with representation of the different decades, thus allowing a sound statistical analysis. In our study the attachment

Table 1. Morphometry of different dimensions ($\bar{x} \pm SD$) in mm of the right atrioventricular orifice

Measurement	Sex	Age groups			
		I (18–40 years)	II (41–65 years)	III (above 65 years)	
Anterior leaflet attachment	Men	33.56 \pm 6.32	34.68 \pm 6.41	34.2 \pm 6.57	
	Women	31.17 \pm 7.10	34.72 \pm 6.08	31.88 \pm 5.84	
Posterior leaflet attachment	Men	28.56 \pm 7.10	28.9 \pm 6.56	38.4 \pm 11.28	
	Women	27.61 \pm 6.61	36.22 \pm 9.80	32.50 \pm 7.85	
Septal leaflet attachment	Men	29.14 \pm 4.59	29.98 \pm 5.29	28.5 \pm 4.64	
	Women	29.5 \pm 3.67	28.97 \pm 5.34	29.75 \pm 6.5	
Frontal dimension	Men	26.33 \pm 4.25	29.42 \pm 5.11	31.1 \pm 3.49	
	Women	24.89 \pm 3.95	26.31 \pm 4.74	29.13 \pm 1.84	
Sagittal dimension	Men	18.67 \pm 4.97	21.1 \pm 5.26	22.8 \pm 4.27	
	Women	18.44 \pm 4.42	18.16 \pm 4.36	22.0 \pm 0.82	
Circumference of the tricuspid valve	Men	107.28 \pm 16.76	115.06 \pm 13.52	120.9 \pm 20.95	
	Women	104.06 \pm 16.76	111.56 \pm 13.17	110.75 \pm 14.38	
Tricuspid valve orifice area	Triangle area	Men and women	365.18 \pm 99.23	391.5 \pm 106.96	431.37 \pm 89.0
	Ellipse area	Men and women	378.33 \pm 140.2	452.07 \pm 177.66	535.99 \pm 96.68

**Figure 3.** A. Triangular shape of the tricuspid orifice in the heart of an 18-year-old man; B. Elliptical shape of the tricuspid orifice in the heart of a 67-year-old man.

length of the septal leaflet was the most stable, whereas the attachment length of the posterior leaflet was the most variable. The significant differences occurred in the attachment length of the anterior leaflet between age groups I and II in women, and in the attachment length of the posterior leaflet between groups II and III in men. The echocardiographic study performed by King et al. [3] in 103 children aged 1 day to 15 years indicated that the tricuspid annular diameter increased in proportion

to the logarithm of the weight and body surface area (BSA). The best predictor of valve annular diameter was a logarithmic function of BSA with a correlation coefficient $r = 0.92$. These authors concluded that knowledge of the normal tricuspid valve annular diameter should be useful in planning palliative or corrective surgery in children with congenital heart disease [11].

The frontal and sagittal dimensions of the right atrioventricular orifice increased in women between

age groups II and III, and in men between all age groups in this study. Sairanen and Louhimo [12] found that the dimensions of the tricuspid valve orifice were closely correlated ($r = 0.96$) with age, body weight, height and BSA according to the logarithmic model in children ranging from 0.27 to 14.6 years. Schnabel et al. [13] showed that in 24 healthy subjects and 74 patients with right ventricular failure the dimensions of the tricuspid valve annulus were equally assessable in both groups, but leaflet thickness and mobility were not significantly different.

Our findings indicated that the right atrioventricular orifice area increased gradually in the three age groups. The results of our research demonstrate that the tricuspid valve orifice areas, expressed as a triangle and an ellipse, increased between age groups I and III from $365.18 \pm 99.23 \text{ mm}^2$ to $431.37 \pm 89.0 \text{ mm}^2$, and from $378.33 \pm 140.2 \text{ mm}^2$ to $535.99 \pm 96.68 \text{ mm}^2$, respectively. In each age group the elliptical area was significantly greater than the triangular area. This study has demonstrated that the shape of the right atrioventricular orifice evolves during life from a triangle to an ellipse. Singh and Mohan [17] found that in 78 healthy subjects aged from 2 months to 50 years the tricuspid valve orifice area reached a value of $4.07 \pm 1.5 \text{ cm}^2$ and ranged from 0.62 to 7.2 cm^2 . The tricuspid valve orifice area was significantly correlated to BSA ($r = 0.77$) and age ($r = 0.61$). These data provide normal values for the right atrioventricular orifice area in normal subjects and support the practice of indexing valve area by body surface area.

We conclude that the dimensions of the tricuspid orifice presented will serve as reference data for further studies and clinical use in patients with various cardiac abnormalities.

REFERENCES

- Carrier M, Hebert Y, Pellerin M, Bouchard D, Perrault LP, Cartier R, Basmajian A, Page P, Poirier NC (2003) Tricuspid valve replacement: an analysis of 25 years of experience at a single center. *Ann Thorac Surg*, 75: 47–50.
- Hvass U, Juliard JM, Assayag P, Laperche T, Pansard Y, Chatel D (1996) Tricuspid autograft for mitral-valve repair. *Lancet*, 347: 659–661.
- King DH, Smith EO, Huhta JC, Gutgesell HP (1985) Mitral and tricuspid valve annular diameter in normal children determined by two-dimensional echocardiography. *Am J Cardiol*, 55: 787–789.
- Khoury GE, d'Udekem Y, Noirhomme P, Verhelst R, Rubay J, Dion R (2000) Transfer of the posterior leaflet of the tricuspid valve to the mitral valve. *J Heart Valve Dis*, 9: 350–352.
- Kutsal A, Yavuz T, Ulasan V (2006) Right atrial and tricuspid hypoplasia. *J Cardiovasc Surg*, 47: 353–354.
- Lamers WH, Viragh S, Wessels A, Moorman AF, Anderson RH (1995) Formation of the tricuspid valve in the human heart. *Circulation*, 91: 111–121.
- Magovern JH, Moore GW, Hutchins GM (1986) Development of the atrioventricular valve region in the human embryo. *Anat Rec*, 215: 167–181.
- Oppido G, Napoleone CP, Ragni L, Turci S, Loforte A, Angeli E, Gargiulo G (2006) Double orifice tricuspid valve in an infant with tetralogy of Fallot. *Ann Thorac Surg*, 81: 1121–1123.
- Piccoli GP, Wilkinson JL, Macartney FJ, Gerlis LM, Anderson RH (1979) Morphology and classification of complete atrioventricular defects. *Br Heart J*, 42: 633–639.
- Radermecker MA, Somerville J, Li W, Anderson RH, de Leval MR (2001) Double orifice right atrioventricular valve in atrioventricular septal defect: morphology and extension of the concept of fusion of leaflets. *Ann Thorac Surg*, 71: 358–360.
- Ramírez S, Cervantes JL (2006) Ebstein anomaly. *Arch Cardiol Mex*, 76 (supl. 2): S65–S68.
- Sairanen H, Louhimo I (1992) Dimensions of the heart and great vessels in normal children. A postmortem study of cardiac ventricles, valves and great vessels. *Scand J Thorac Cardiovasc Surg*, 26: 83–92.
- Schnabel R, Khaw AV, von Bardeleben RS, Strasser C, Kramm T, Meyer J, Mohr-Kahaly S (2005) Assessment of the tricuspid valve morphology by transthoracic real-time-3D-echocardiography. *Echocardiography*, 22: 15–23.
- Shatapathy P, Aggarwal BK, Kamath SG (2000) Tricuspid valve repair: a rational alternative. *J Heart Valve Dis*, 9: 276–282.
- Siebert FM, Lorenzo FJM, Rojas TM, Becerra PE, Martinez EF, Dans CA (1981) Tricuspid atresia with hypoplasia of aortic isthmus in absence of transposition of great vessels. *An Esp Pediatr*, 14: 117–121.
- Silver MD, Lam JHC, Ranganathan N, Wigle ED (1971) Morphology of the human tricuspid valve. *Circulation*, 43: 333–348.
- Singh B, Mohan JC (1994) Atrioventricular valve orifice areas in normal subjects: determination by cross-sectional and Doppler echocardiography. *Int J Cardiol*, 44: 85–91.
- Skwarek M, Grzybiak M, Kosiński A, Hreczecha J (2004) Notes on the morphology of the tricuspid valve in the adult human heart. *Folia Morphol*, 63: 319–324.
- Skwarek M, Hreczecha J, Dudziak M, Jerzemowski J, Wilk B, Grzybiak M (2007) The morphometry of the accessory leaflets of the tricuspid valve in a four cuspidal model. *Folia Morphol*, 66: 323–327.
- Skwarek M, Hreczecha J, Dudziak M, Jerzemowski J, Grzybiak M (2007) The morphology and distribution of the tendinous chords and their relation to the papillary muscles in the tricuspid valve of the human hearts. *Folia Morphol*, 66: 314–322.